

Treatment Center: _____

Civic registration number: _____

Last name: _____ First name: _____

Q37.5

Age at registration: 5 y 10 y 16 y 19 y 1y p-o

Date at registration: No show No further follow-ups

Examiners name: _____

Classification of occlusion Modified Huddart Bodenham index (at 5, 10, 19 years and at 1 year after ortognathic surgery)

Anterior score / central incisors: _____ Posterior score / right side: _____ Posterior score / left side: _____ Not possible

INCISOR SCORING

CANINE SCORING

MOLAR SCORING

Calculation of MHB

- Missing central incisor - equal score as other central
- Missing canine - score determined by alveolar ridge
- Missing primary molar/premolar - equal score as adjacent tooth/alveolar ridge if both are missing

All ages: both centrals=sum of scores for 2 pairs of teeth

5 yrs: canine+2 primary molars=sum of scores for 3 pairs of teeth.

10, 19 yrs and 1y post-surgery: canine+premolars+1st molar=sum of scores for 4 pairs of teeth

<p>At 5 years: Attack</p> <p><input type="checkbox"/> Not possible</p>	<input type="checkbox"/> <input type="checkbox"/>	<p>1. Positive overjet with average inclined or retroclined incisors. No crossbite/open bites.</p>		
	<input type="checkbox"/>	<p>2. Positive overjet with average inclined or proclined incisors. Unilateral crossbite/cross bite tendency. Open bite tendency around cleft site.</p>		
	<input type="checkbox"/>	<p>3. Edge-to-edge bite with average inclined/proclined incisors or reverse overjet with retroclined incisors. Unilateral crossbite. ±Open bite tendency around cleft site.</p>		
	<input type="checkbox"/>	<p>4. Reverse overjet with average inclined or proclined incisors. Unilateral crossbite ± bilateral crossbite tendency. ±Open bite tendency around cleft site.</p>		
	<input type="checkbox"/>	<p>5. Reverse overjet with proclined incisors. Bilateral crossbite. Poor maxillary arch form and palatal vault anatomy.</p>		

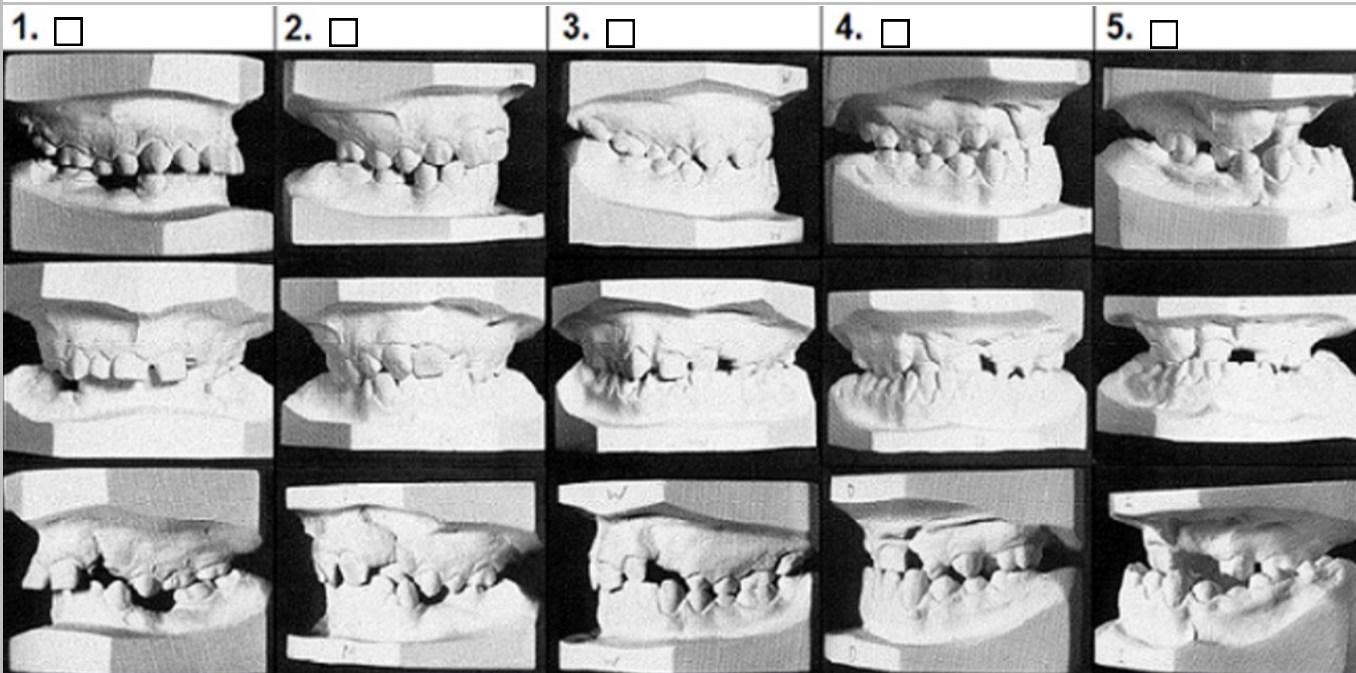
At 10 & 19 years, 1 year after orthognathic surgery:

GOSLON Not possible

Anteroposterior assessment: Dentoalveolar compensation with marked proclination of upper incisors and retroclination of lower - a higher category should be considered. If incisor inclination or mandibular overclosure exaggerates the severity - a lower score should be considered

Vertical assessment: Favorable vertical features (i.e. deep overbite) do not indicate modification of category except in borderline cases. A reduced overbite or anterior open bite suggests higher score.

Transversal assessment: A normal transverse relationship or a crossbite that can be treated orthodontically does not indicate a change of group. Marked maxillary arch narrowing with bilateral crossbite could indicate a more severe category.



At 5, 10, 19 years and at 1 year after ortognathic surgery:

Photos Yes No Not possible

Casts Yes No Not possible

Cephalometric Radiograph Yes No Not possible

At 10 years:

Agensis / permanent teeth, tooth name : _____ (exclude eights) Not possible

At 10, 19 years and at 1 year after ortognathic surgery:

Cephalometrics SNA ° SNB ° NaPg ° NSL/NL ° NSL/ML ° Not possible

At 16 years;

Bone grafting Yes No

Orthodontics before bone grafting Yes No

Score; bone level in the cleft area estimated in relation to the root length of the tooth mesial of the cleft

Right side: Not applicable 0: Bone missing 1: <3/4 2: >=3/4

Left side: Not applicable 0: Bone missing 1: <3/4 2: >=3/4